SICOT - Prague - 16th september 2006

Anatomy and Biomechanics of the instable ankle

Docteur E. Toullec
Polyclinique de Bordeaux –Tondu – 33000 Bordeaux
eric.toullec2@wanadoo.fr

1 – the osseous stability

the tibiofibulotalar joint seems stable because of a conformation of mortise…

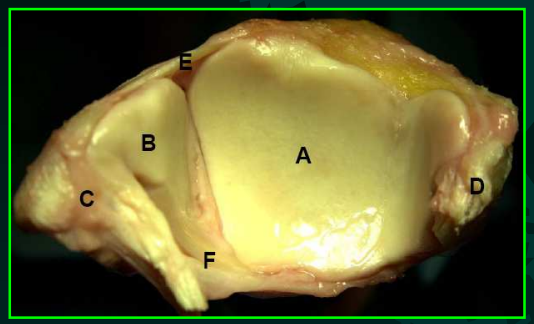

Inferior view

Tibiofibular mortise

- **3 malleoli**
- **Lateral malleolus lower**
  = lateral stabilisation

Dorsal view

Talar tenon

The talar surface is wider in the front part
= stabilisation in dorsal flexion

Some anatomical deformities can modified this stability

Tibial valgus after trauma in the child period

→ The lateral malleolus is too hight

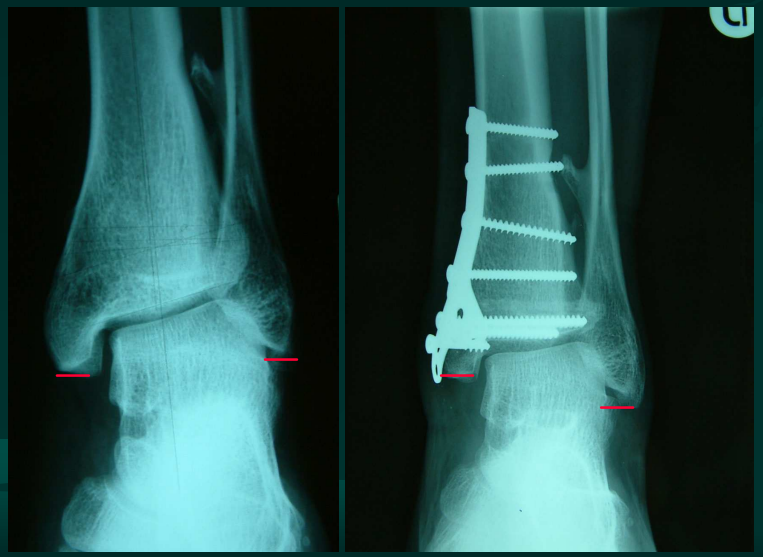

- **lateral malleolus too posterior**

  Berkowitz CP, Kim DH : Fibular position in relation to lateral ankle instability.
  Foot Ankle Int. 2004 May; 25(5):318-21.

- **Malunion with rotation**

However , the tibiotarsal joint is incongruent

→ Trunqued cone shape

→ stress lesions if desaxation :

- on the malleoli = stress fracture
- tendinomuscular overuse : fibular , tibial posterior splint
- joint disease :

Osteochondral lesion

Evolutive arthritis

Can we prevent this evolution ?

→ **Reaxation and stabilisation before joint disease**

without stress

with stress in varus

yes →

+ calcaneus lateral translation

Ligamentoplasty ?

without stress

with stress in varus

NO →

Be careful after a surgical reaxation of the hindfoot

→ the TT joint may be more painful after if arthritis

Painful instability after a ligamentoplasty man of 30 years old

Painful ankle after calcaneal osteotomy and basal elevation of the 1srt metatarsal

Tibiotarsal joint functionaly associated with the hindfoot and the midfood

= to transmit the vertical force of the lower limb to the horizontal force of the foot

→ lateromedial and rotational stability

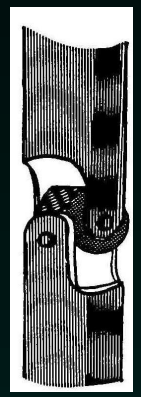

Torque complex

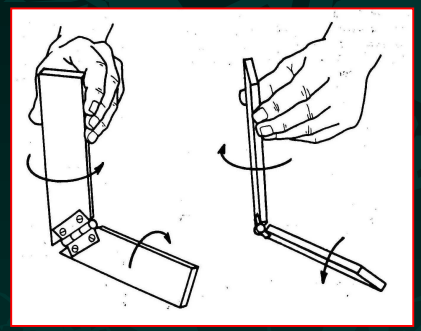

In the hindfoot

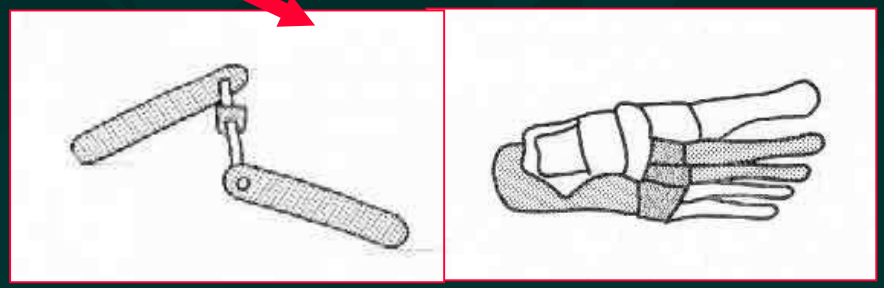

In the midfoot (Kowalski)

Midfoot lesion in sprain in inversion mechanism

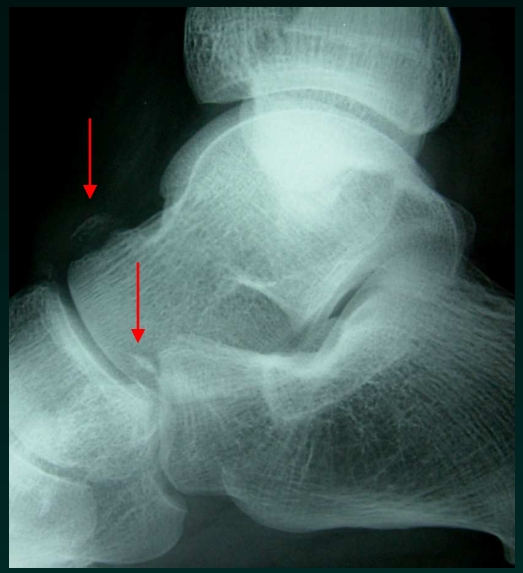

Chopart sprain
(bifurcate ligament)

Rostrum fracture
(bifurcate ligament)

5th metatarsal fracture

Midfoot lesion in sprain in inversion mechanism

Long term consequences

Talonavicular arthritis
10 years after a sprain

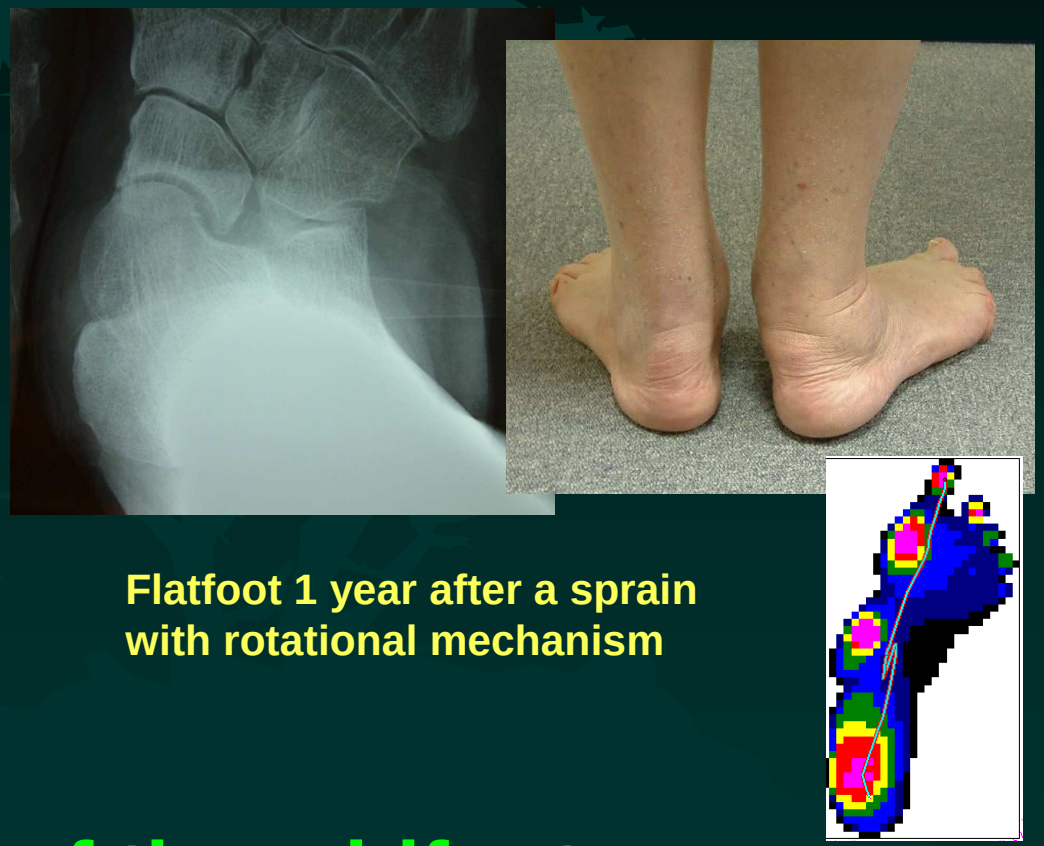

Flatfoot 1 year after a sprain
with rotational mechanism

Test the laxity of the midfoot

Interest in these cases to stabilise the midfoot during the ligamentoplasty :

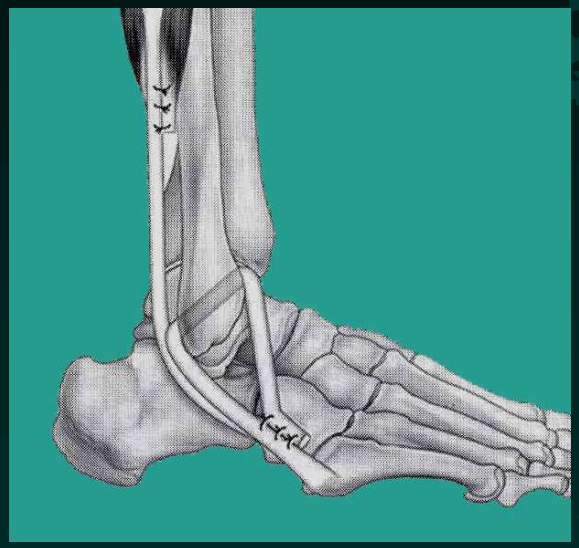

Castaing

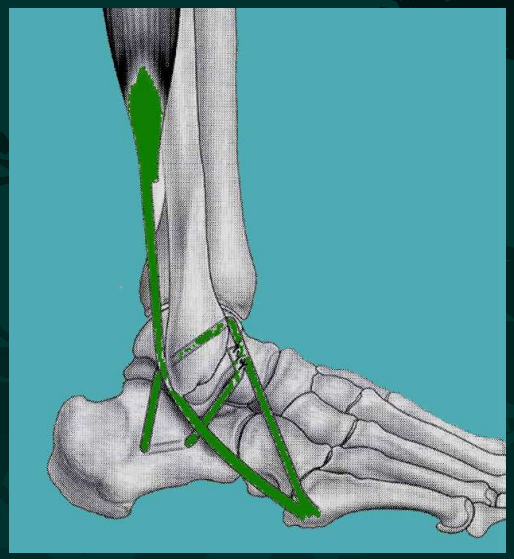

Christman Snook

Or with arthrodesis of the Chopart joint ?

2 –the ligamentous stability

A – lateral ligament = 3 fascicles

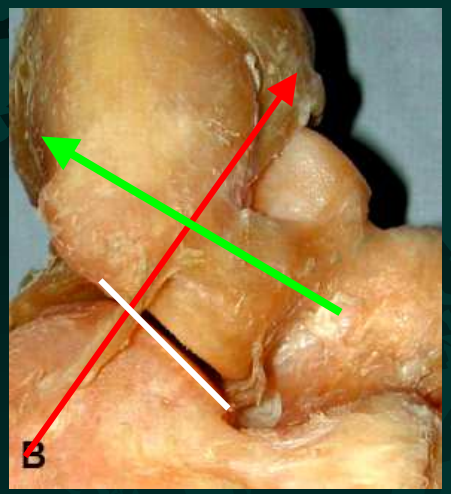

Anterior fibulotalar ligt

Horizontal
lateral anterior fascicle

post.fibulotalar ligament :
intra-articular

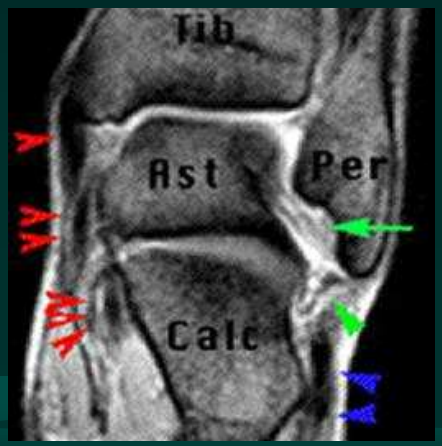

Peroneocalcaneal ligament :

Anterior insertion on the fibula
Perpendicular to the subtalar joint
= Parallele to the axis of Henke
Lateral posterior fascicle (rotation)

Ligamentous stability

A – lateral ligament

Lesional mechanism

Varus : foot on the ground ,

above all fibulocalcaneal and talocalcaneal lesion
subtalar lesions++

Rotation : foot in weightbering

lateral and medial lesion , posterior ankle area++

Inversion ++: foot generally not in weightbearing

lateral and anterior lesions (midfoot ++)

Ligamentous stability

A – for a lateral ligament lesion

1. To understand the mechanism if possible

2. To do a complete analysis before surgery :
   - → dynamic echography
   - → CT scan with contrast : articular lesions
   - → MRI : the most interesting in the associated lesions

3. To use of a procedure that involve all the lesion

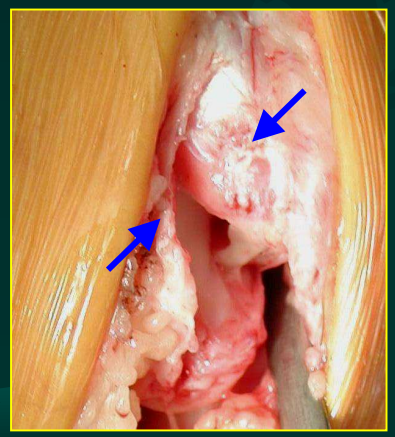

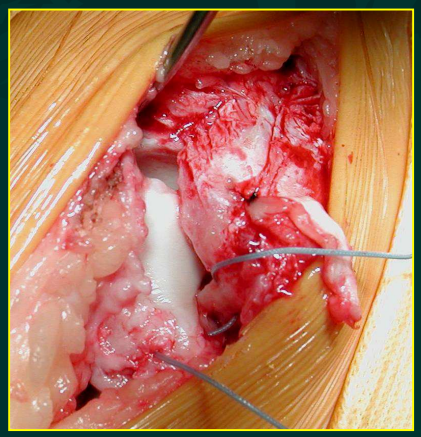

Don’t forget to correct the posterior talofibular ligament

Ligamentous stability

B – Médial ligament

Superficial layer

contact with navicular bone and tibial posterior tendon

Tibiocalcanear ligament

Tibionavicular ligament

Tibiospring ligament

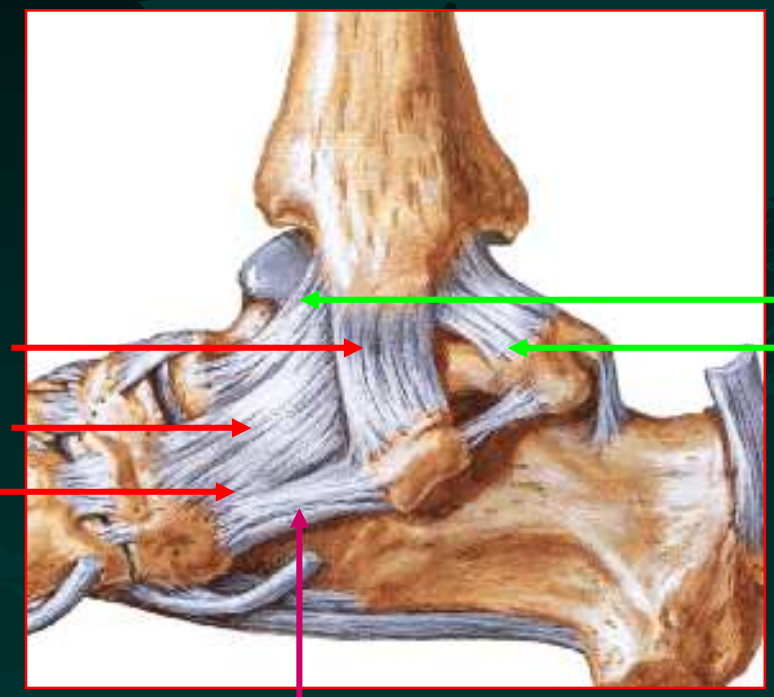

Spring ligament

Deep layer

Intra-articular extrasynovial

Tibiotalar ligament
anterior
posterior

Boss A., Hintermann B. : Anatomical study of the medial ankle ligament complex. Foot & Ankle Int., N°6 , june 2002 , 547-553

Ligamentous stability

B - Medial ligament

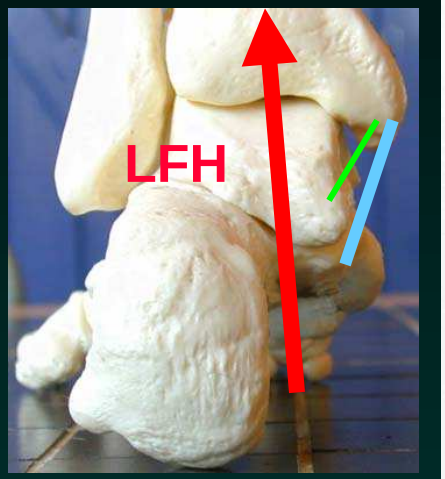

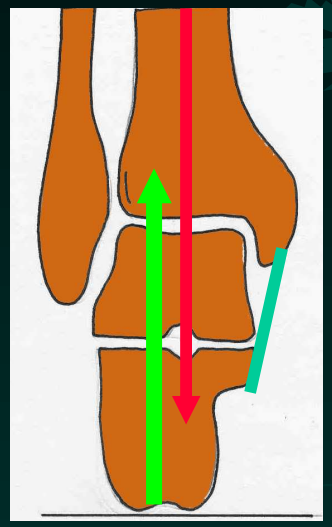

Shock absorber mechanism
during heel strike ((Kowalski)

Medial ligt rupture

→ hindfoot valgus

Chronic medial instability (rare)= flatfoot

Medial ligt suture &
calcaneus medial translation

Ligamentous stability

C- ankle syndesmosis

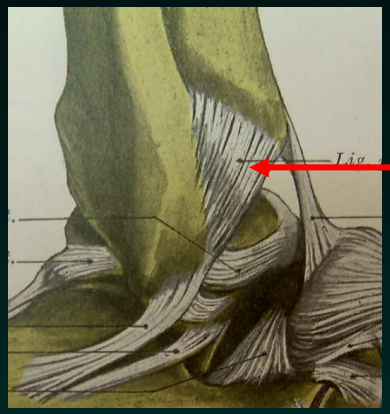

Anterior inferior tibiofibular ligt.

Posterior inferior tibiofibular ligament

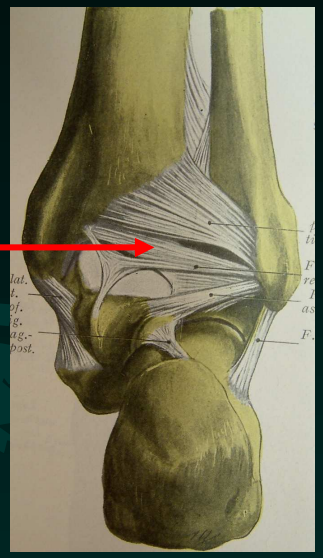

+ interosseous tibiofibular ligt
+ interosseous membrane

Roles:

- To keep the flexible distance between tibia and fibula = lateromedial stability
- Oblique orientation = rotational stability

Pena F, Coetze C : Ankle syndesmosis injuries. Foot ankle clinics . March 2006 : 35-50.

Ligamentous stability

D – rotational stability = complex

Confirmed by the anatomy : oblique orientation of the ligaments and tendons

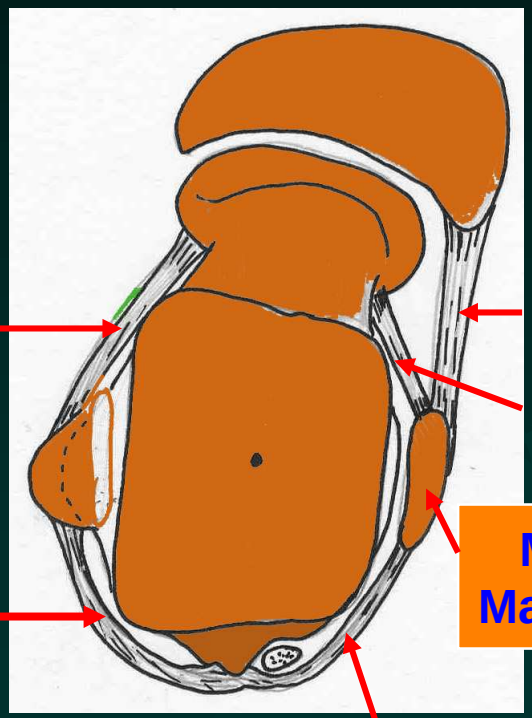

Anterior painful lesions
(fibrous anterolateral conflict, Impingement exostosis)

Posterior painful lesions
(posterolateral tubercle fracture, fibrous post. conflict, posterior subtalar arthritis)

Ligamentous stability

D – rotational stability

Medial tibiotarsal arthritis +
Anterior subtalar arthritis
20 years after ankle sprain

Subtalar arthrodesis in the first step to place the talus on the calcaneus

Second step 1 month after : ankle arthroplasty
(result 1 year after)

3 – the tendinous stability

- **angulation over the malleoli :**
  - → pulley = stabilisation of the tendon
  - → important variation of lenght
    (inversion : 21 mm for TP , 24 mm for PL)

- **The ankle stabilisator tendons cross over the midfoot with an oblique orientation = rotational stability**

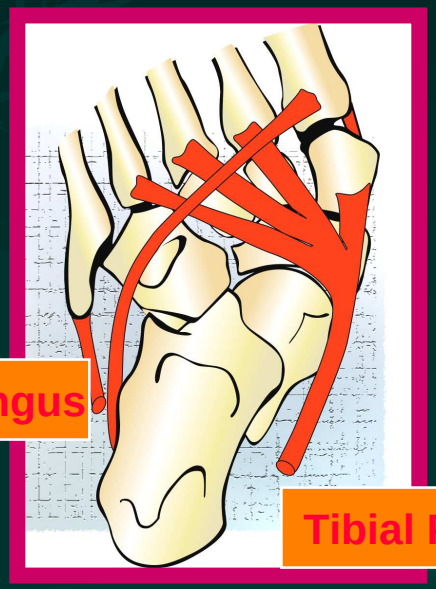

Tendinous stability

medial stabilisator tendons

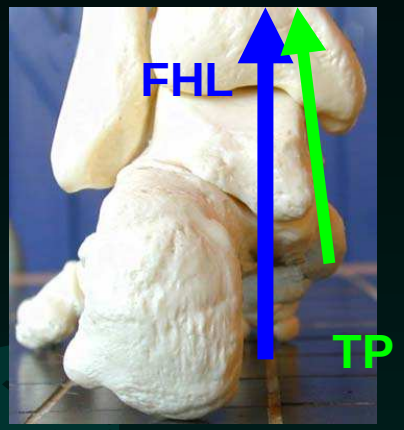

→ **Rare injuries in ankle sprain**

Tibial posterior tendon :

Sometimes , its rupture involve a flatfoot in association with a lesion of the medial ligament :

If no valgus : medial ligt & spring ligt & TP repair

If valgus : the ligament and tendon repairing is not sufficient :

a calcaneus medial translation is necessary associated

Tendinous stability

The fibular tendons

- Close to the posterior and intermediate fascicle of the lateral ligament
  → actif lateral stabilisator of the ankle

- Distal insertion on the midfoot
  Peroneus brevis = abductor
  peroneus longus = eversor
  → action / subtalar and midtarsal joint

- Role in the proprioception



Foot & Ankle Int. , 2002 , feb 123-129

J. Foot Ankle Surg. 2001 jul – Aug 240-251

Tendinous stability

Fibular tendons

Lesions meet in the ankle sprains : frequent factors of risk or consequences

Peroneus tendon weakness

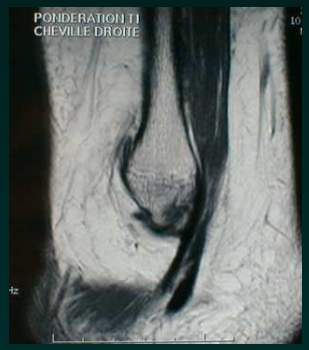

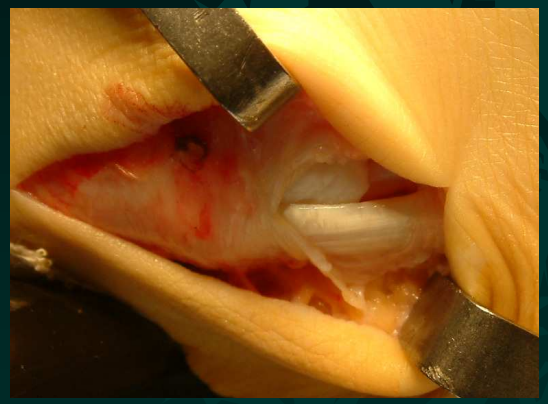

luxation

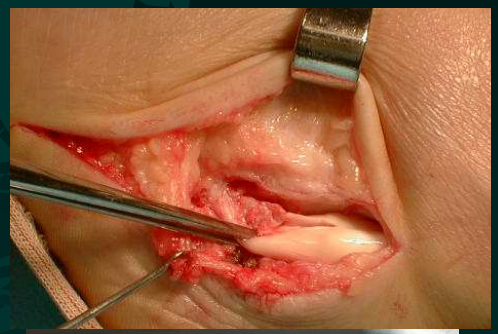

Os peroneum fracture

tendinopathy

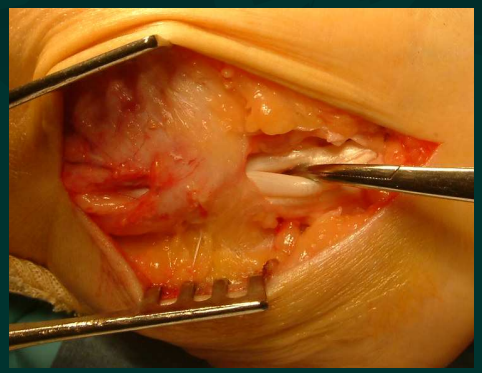

splint

Tendinous stability

Achilles (gastrocnemius) tendon

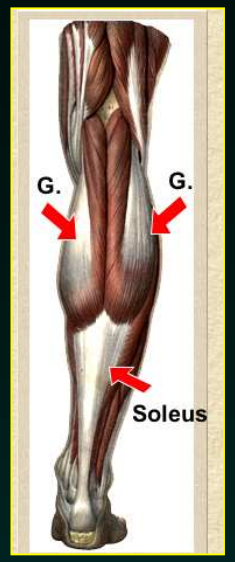

Generally , not injuried during ankle sprain but sometimes a factor of ankle instability :
Its retraction involves :
- a limitation of the dorsal flexion of the ankle
- hindfoot varus or valgus compensation

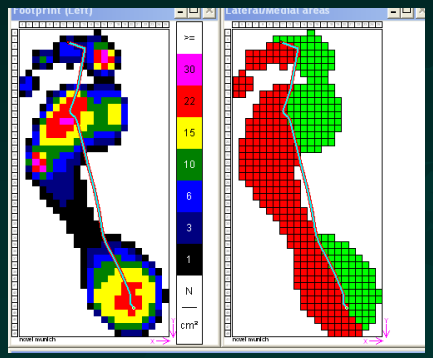

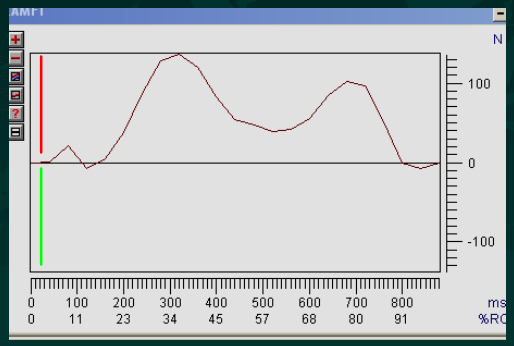

Lateral medial force index

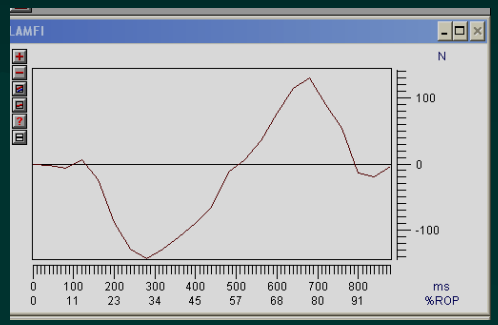

= gastrocnemius retraction

conclusion

The factors of stabilisation of the ankle are complex.
The apparent osseous stability is attenued by a rotational mobility.

The ligaments play a role of medial and lateral stability
but also rotational
helped by the muscle stabilisators of the hindfoot and the ankle
which action is also focalised on the subtalar
and talonavicular joints (coxa pedis).

The dynamic pedobarography seems today a very interesting exam
to analyse this rotational mobility during weightbearing
(lateral medial force index)

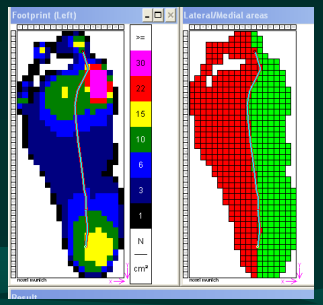

Thanks to :
B. Hinterman (Bâle) , M. Maestro (Nice) ,
B.Ferré (Cap d'Agde) , F. Bonnel (Montpellier)