Subtalar joint damage associated with lengthening calcaneal osteotomy for adult flatfoot

E. TOULLEC, F. BONNEL, H. BOUIN, JA. COLOMBIER and the AFCP* (France)

Introduction

During the calcaneal lengthening osteotomy described by Evans for adult flatfoot deformity, the bone cut crosses the anterior calcaneal apophysis. This may result in the medial anterior subtalar surface being damaged. In this study, post-operative CT scans with 3D reconstruction of the calcaneus were performed to evaluate this damage.

Material and method

Twelve post-operative CT scans were analyzed (8 men, 4 women, mean age 50 years, mean follow-up 28 months). Damage to the medial anterior subtalar joint, the shape of the anterior surface (Bunning classification), the distance to the calcaneocuboid joint and the orientation of the cut were evaluated. Progression of osteoarthritis (AO) in the joint was noted at latest follow up.

Results

Damage to the joint surface (3 cases) :
1 in the anteromedial, 2 in the anterolateral surface
(one case with the cut at 5mm from the CC joint)
Bunning classification : Type A1= 3, B1= 3, B2= 3, B3 =3.
The distance between the cut and
the calcaneocuboid joint was 12.7mm (5 to 15mm).
The orientation of the cut was
perpendicular to the longitudinal axis
of the calcaneus in 5 cases, posterior in 6 and anterior in 1.
No painful arthritic joint.

Intra-articular damage in 25% of cases

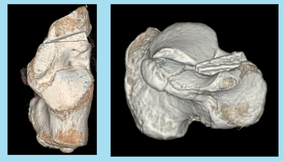

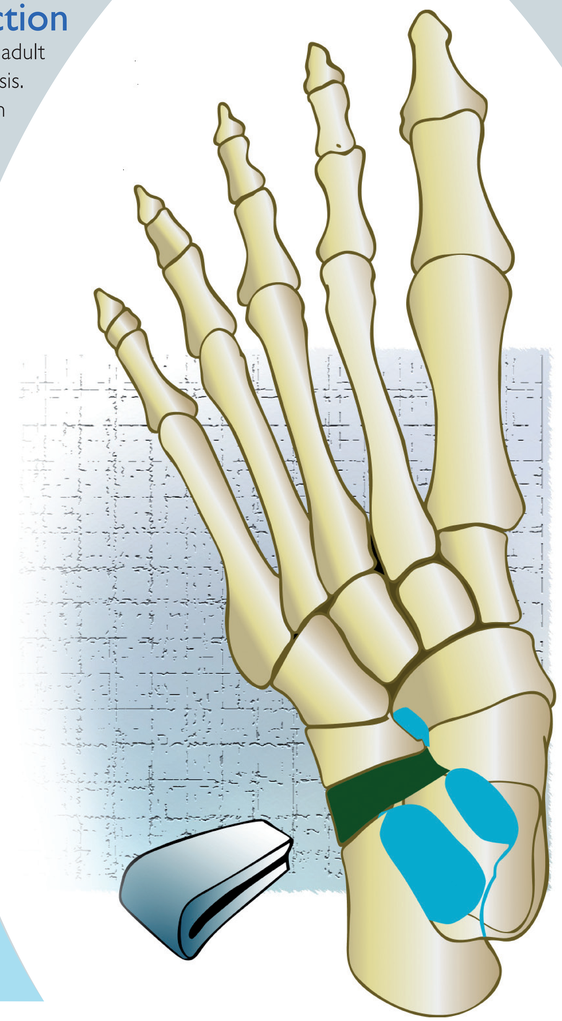

Discussion

In this short series, the rate of type B (75%) was more important than in previous cadaveric studies. (Sarafian 64%, Hyer 56%, Ragad 46%). In flatfoot, type B seems to be more frequent maybe due to the excess of pressure on the coxa pedis.
The distance to the calcaneocuboid joint was tolerated between 11 to 15mm as described by Hyer.
The direction of the cut parallel to the joint was easier to define thanks to a needle or a K wire in the joint.
In type A1, A2, B1, the cut caused no damage.
In type B3, it crossed just distally to the joint.
In type B2, the cut was always intra articular.
But why no arthritic evolution ? One explanation was to consider that the intra articular cut in the deep part of the joint and the decompression of the coxa pedis due to the positionning of the navicular in front of the talus head may prevent the arthritis evolution.
The second option was to consider it was better to cross between the anteromedial and the posterior surface but the effect of the osteotomy was not the same.

Conclusion

Some anatomic shapes of the subtalar surfaces of the calcaneus are automatically damaged in the Evans calcaneal lengthening osteotomy.

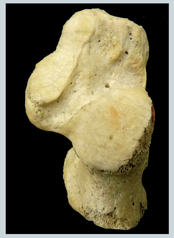

Bunning classification

A1 B1 B2 B3

*AFCP: French Association for Foot Surgery toullec.